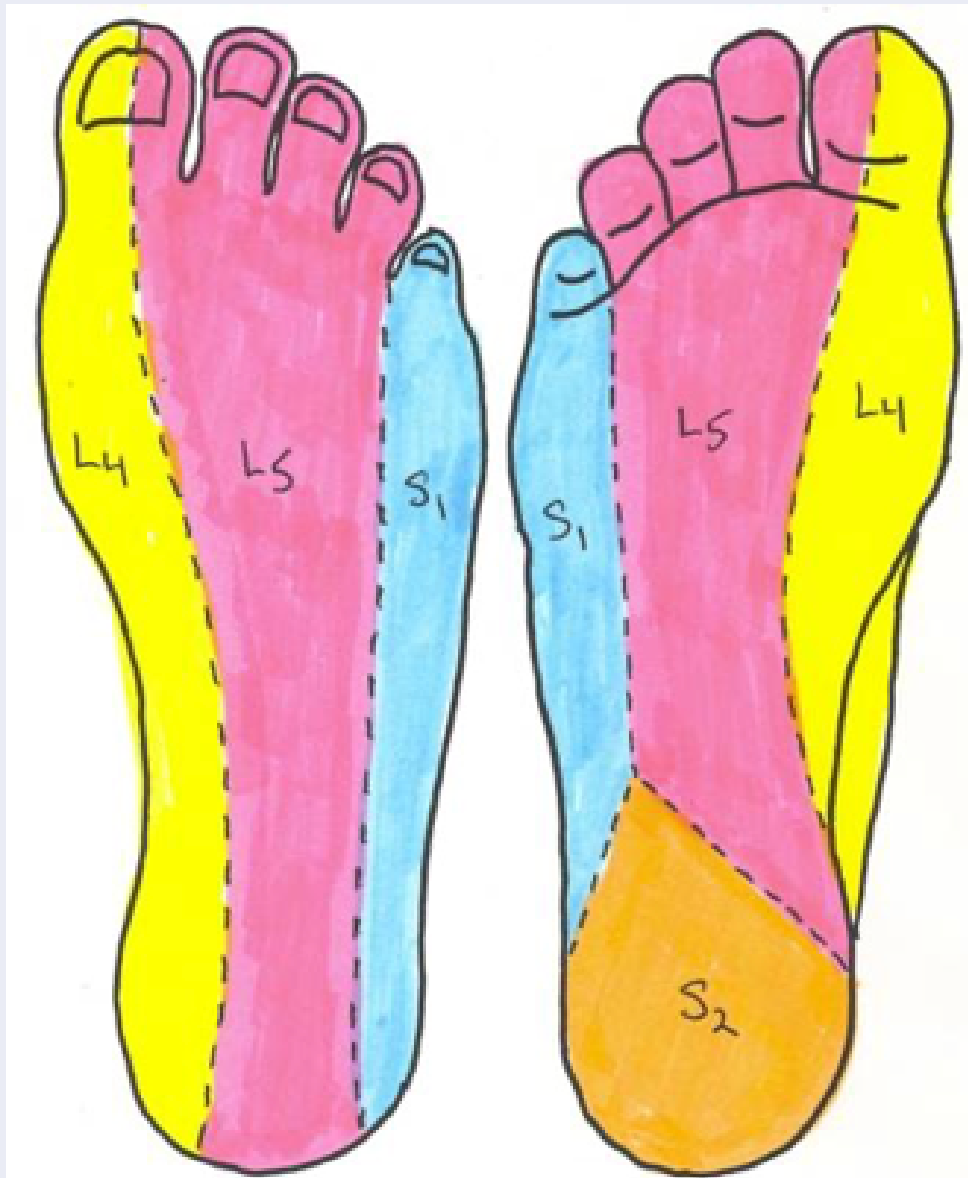


# Lumbosacral Radiculopathy

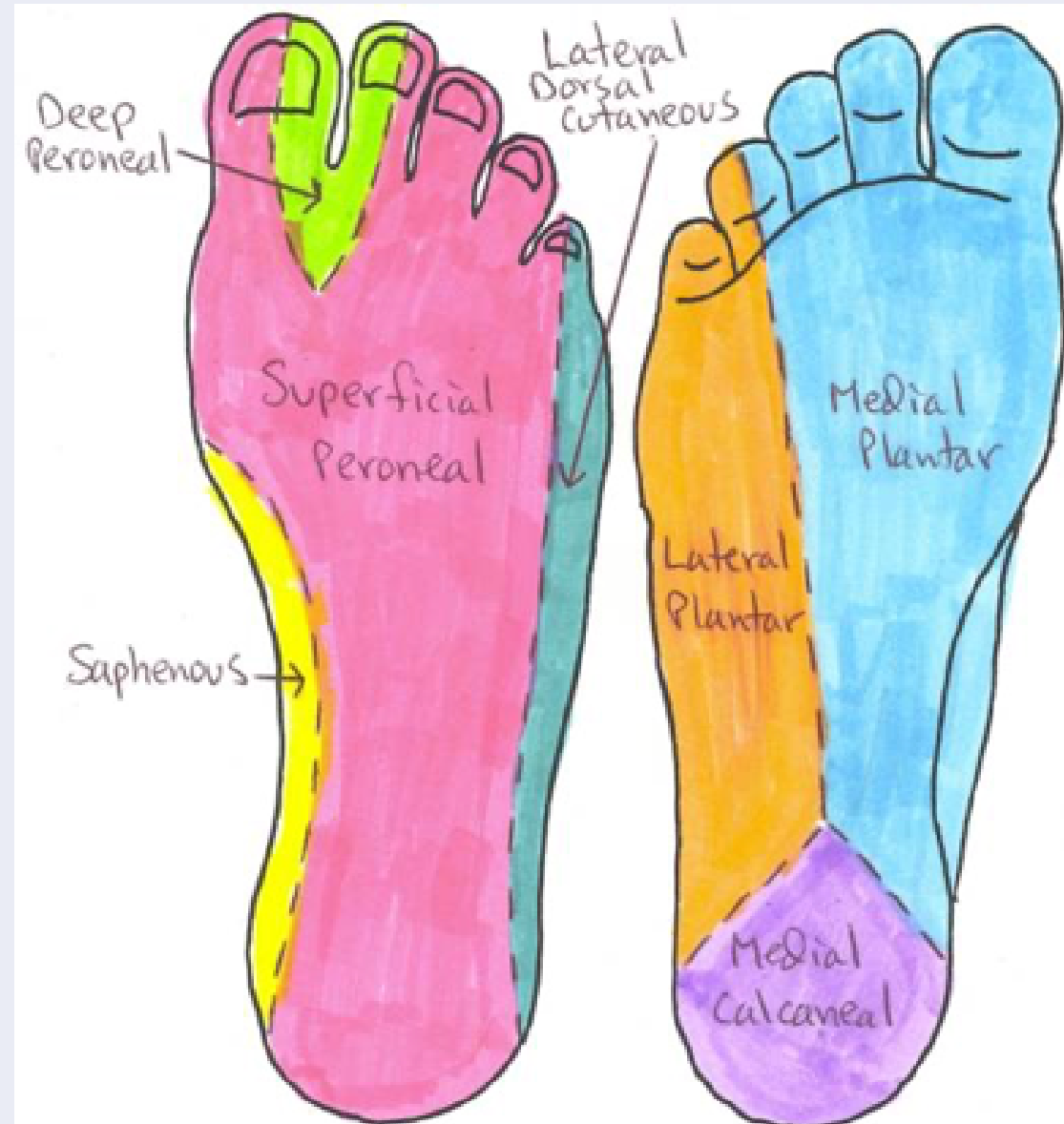Nerve Root	Pain/symptoms	Sensory Loss	Muscle Weakness	Deep tendon reflex loss
L1 (very uncommon)	Inguinal region	Inguinal region	Hip flexion	
L2 – L4 (most commonly seen in older patients with spinal stenosis)	-Back pain radiating to the anterior thigh -Medial lower leg pain	-Anterior thigh -Medial lower leg	Hip Flexion Hip adduction Knee extension	-Patellar tendon
L5 (most common radiculopathy)	-Back pain radiating to the buttock, lateral thigh, dorsal foot, great toe	-Lateral calf -Dorsal foot -1 <sup>st</sup> interdigital space	-Hip abduction -Knee flexion -Foot dorsiflexion -Foot eversion and inversion	
S1 (commonly caused by L5-S1 disc herniation)	-Back pain radiating to the buttock, lateral/posterior thigh, posterior calf, lateral or plantar foot	-Posterior calf -Lateral or plantar foot	-Hip extension -Knee flexion -Plantarflexion of the foot	-Achilles tendon
S2-S4 (less commonly seen location)	-Sacral or buttock pain radiating to the posterior leg or perineum	-Medial buttock -Perineal or perianal region	-Minimal weakness -urinary and/or fecal incontinence -Sexual dysfunction	

# Dermatomes/Innervation of the Foot



## Dermatomes of the Foot

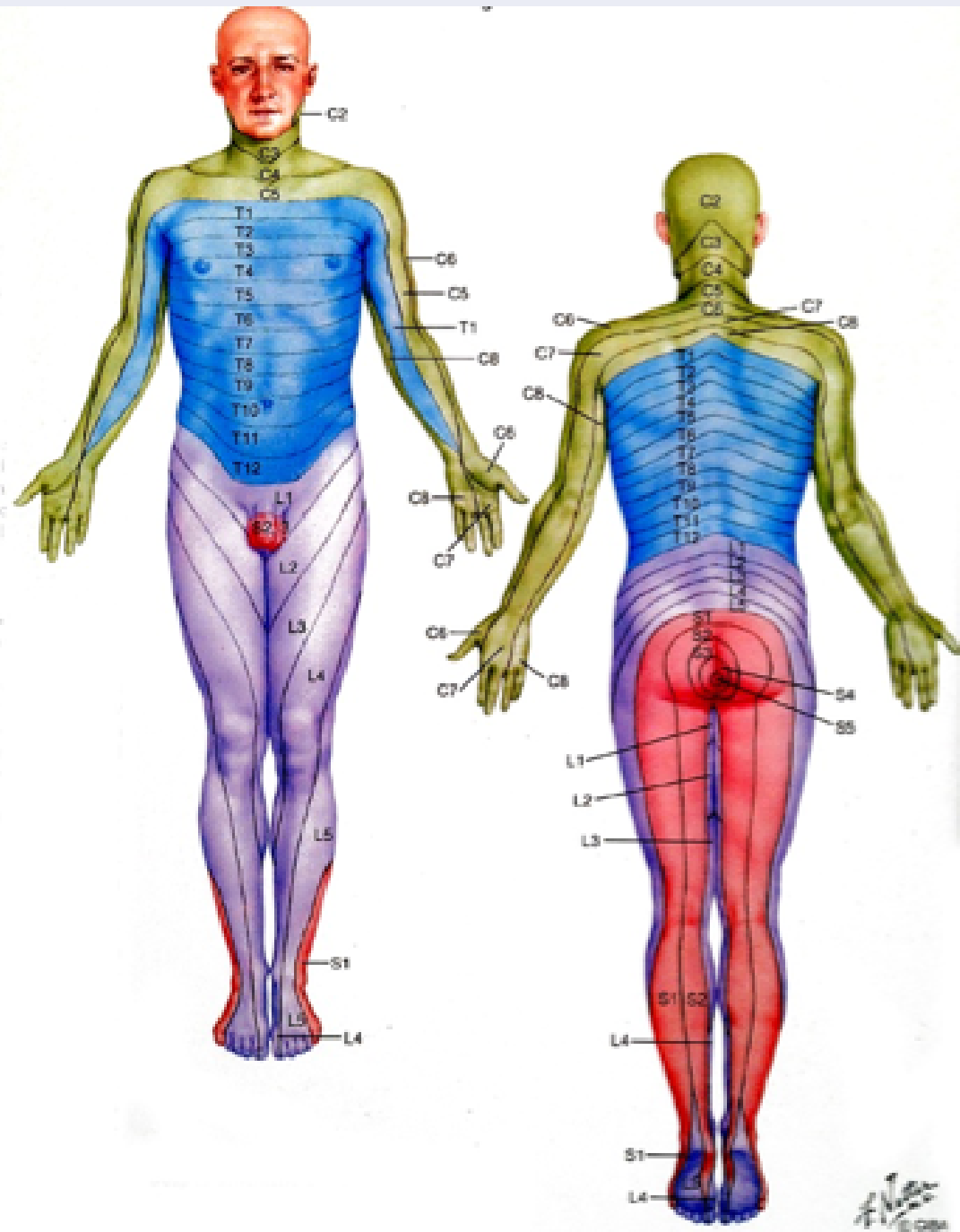
L4, L5, S1, S2



## Cutaneous Nerves of the Foot

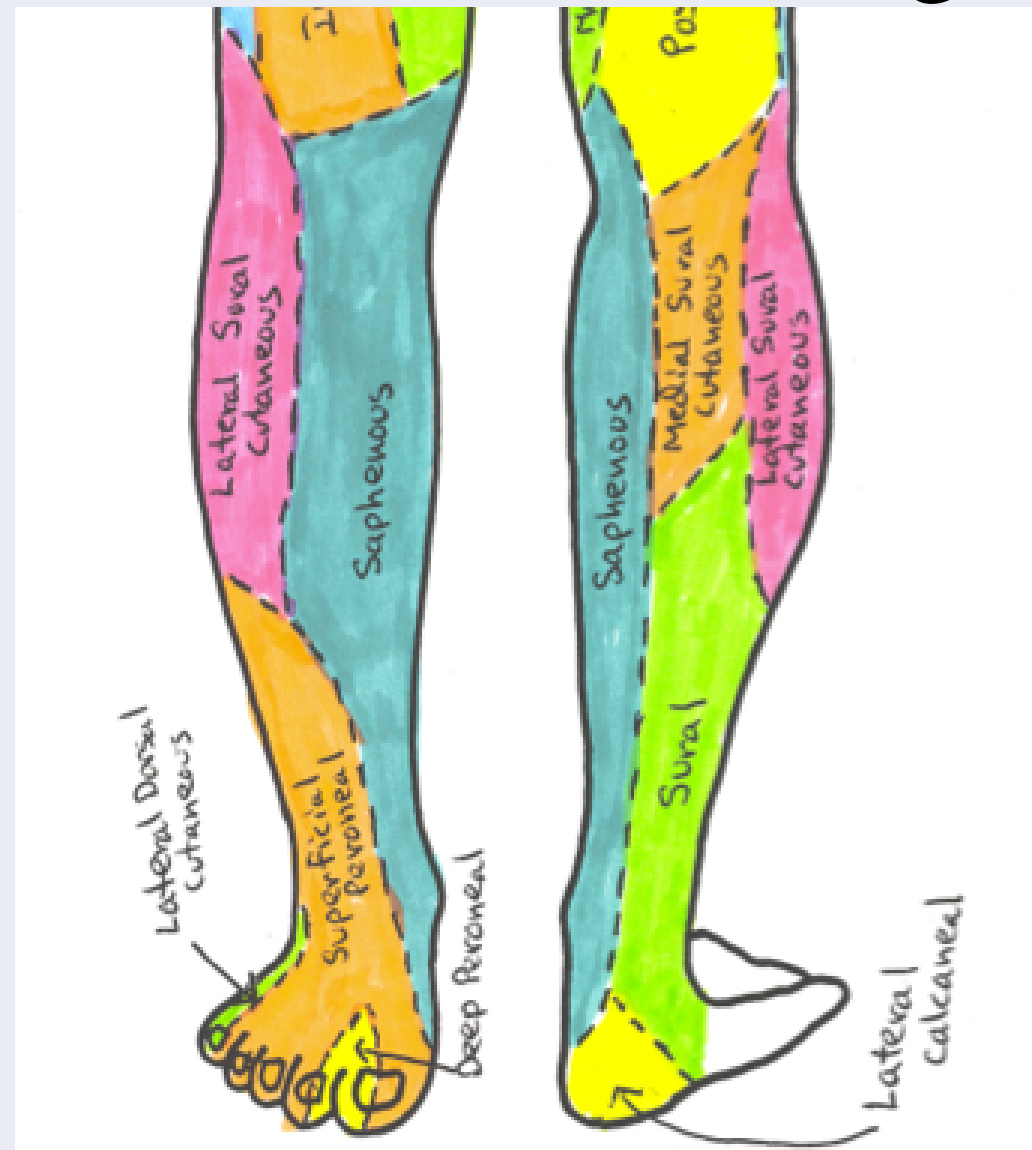- 1) saphenous
- 2) Superficial peroneal
- 3) Deep peroneal
- 4) Lateral dorsal cutaneous (sural)
- 5) medial/lateral plantar
- 6) medial/lateral calcaneal

# Dermatomes/Innervation of the Leg



## Dermatomes of the Leg

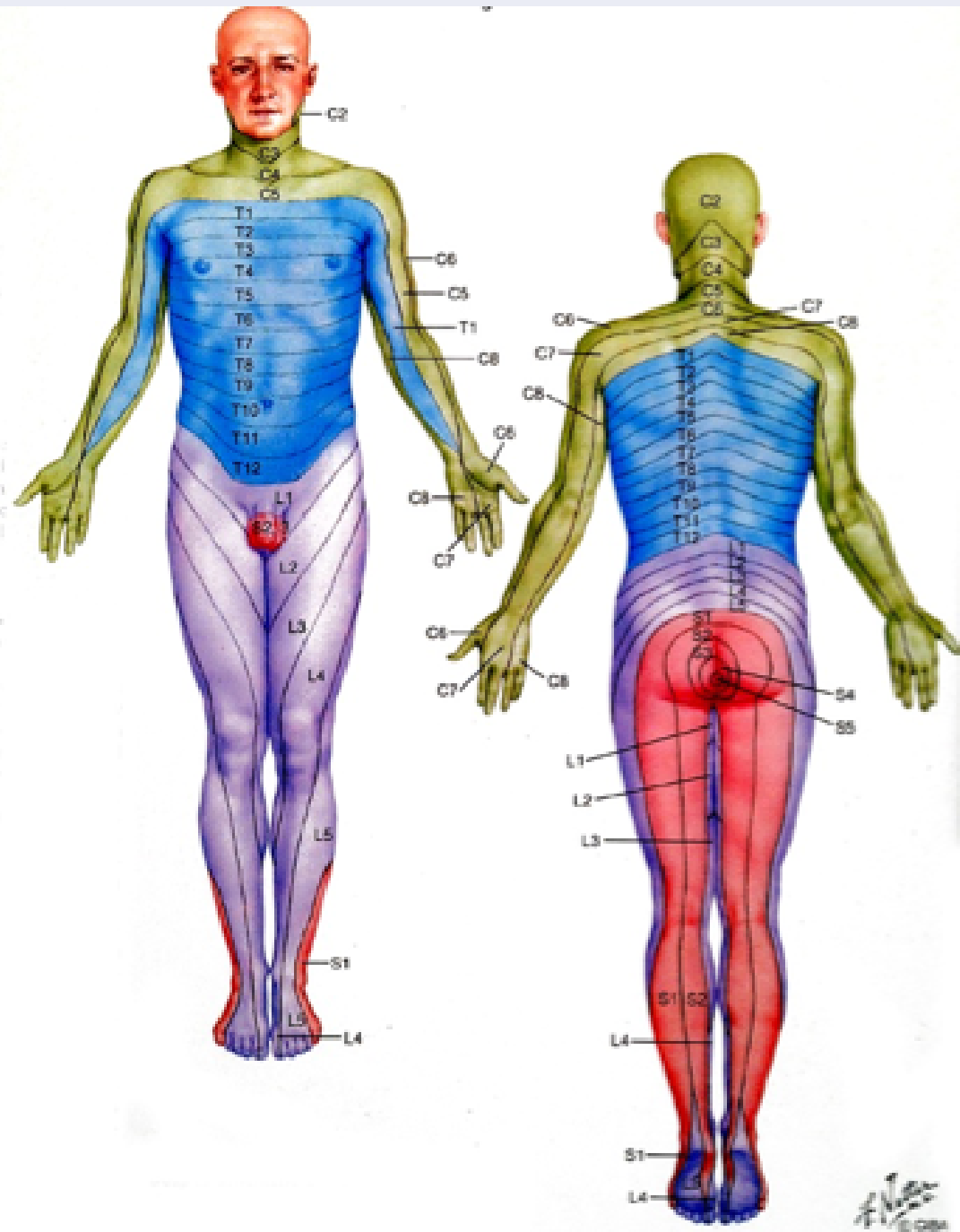
L3, L4, L5, S1, S2



## Innervation of the Leg

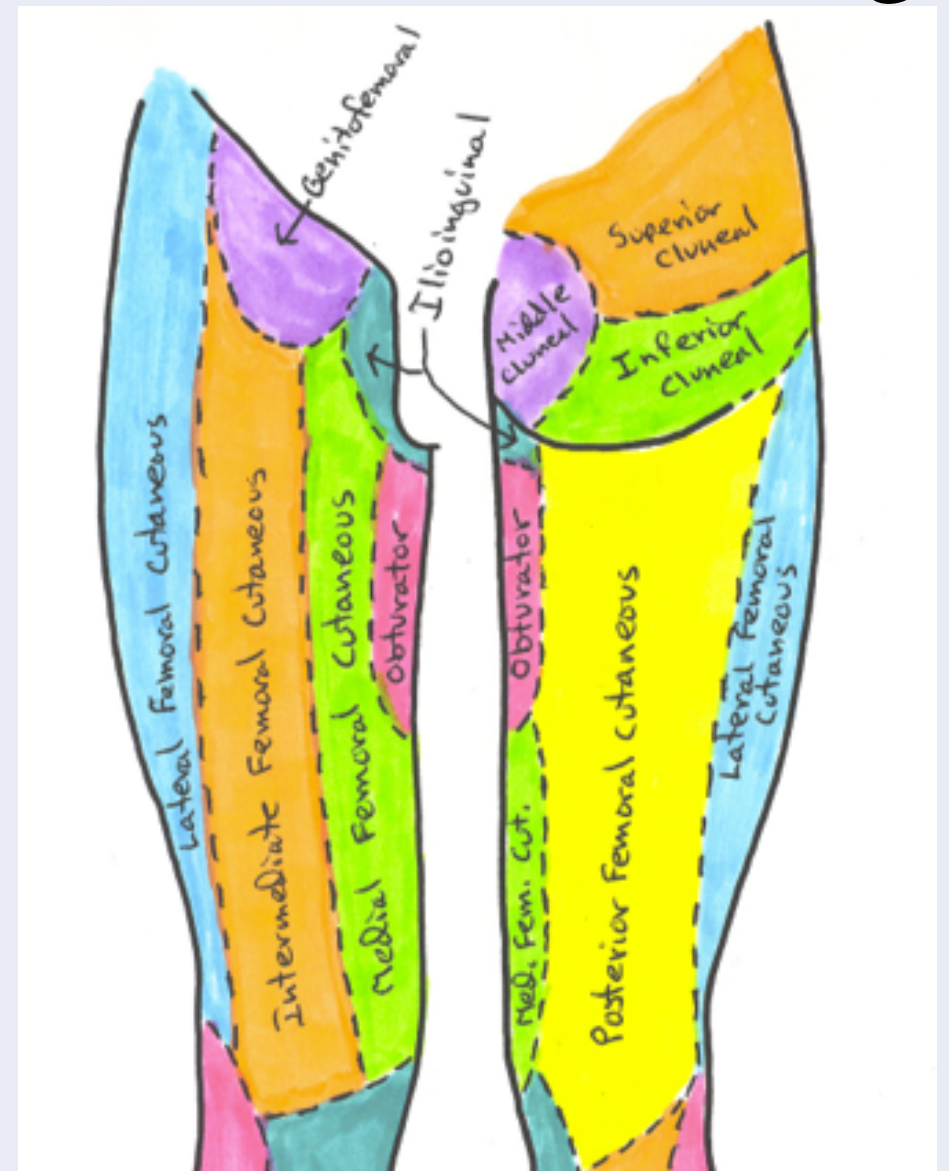
- 1) Saphenous nerve
- 2) Superficial peroneal
- 3) Lateral sural cutaneous
- 4) Medial sural cutaneous
- 5) Sural

# Dermatomes/Innervation of the Thigh



## Dermatomes of the Leg

L1, L2, L3, L4, L5, S1, S2, S3



## Innervation of the Thigh

- 1) Gluteal Region
- 2) Thigh Region