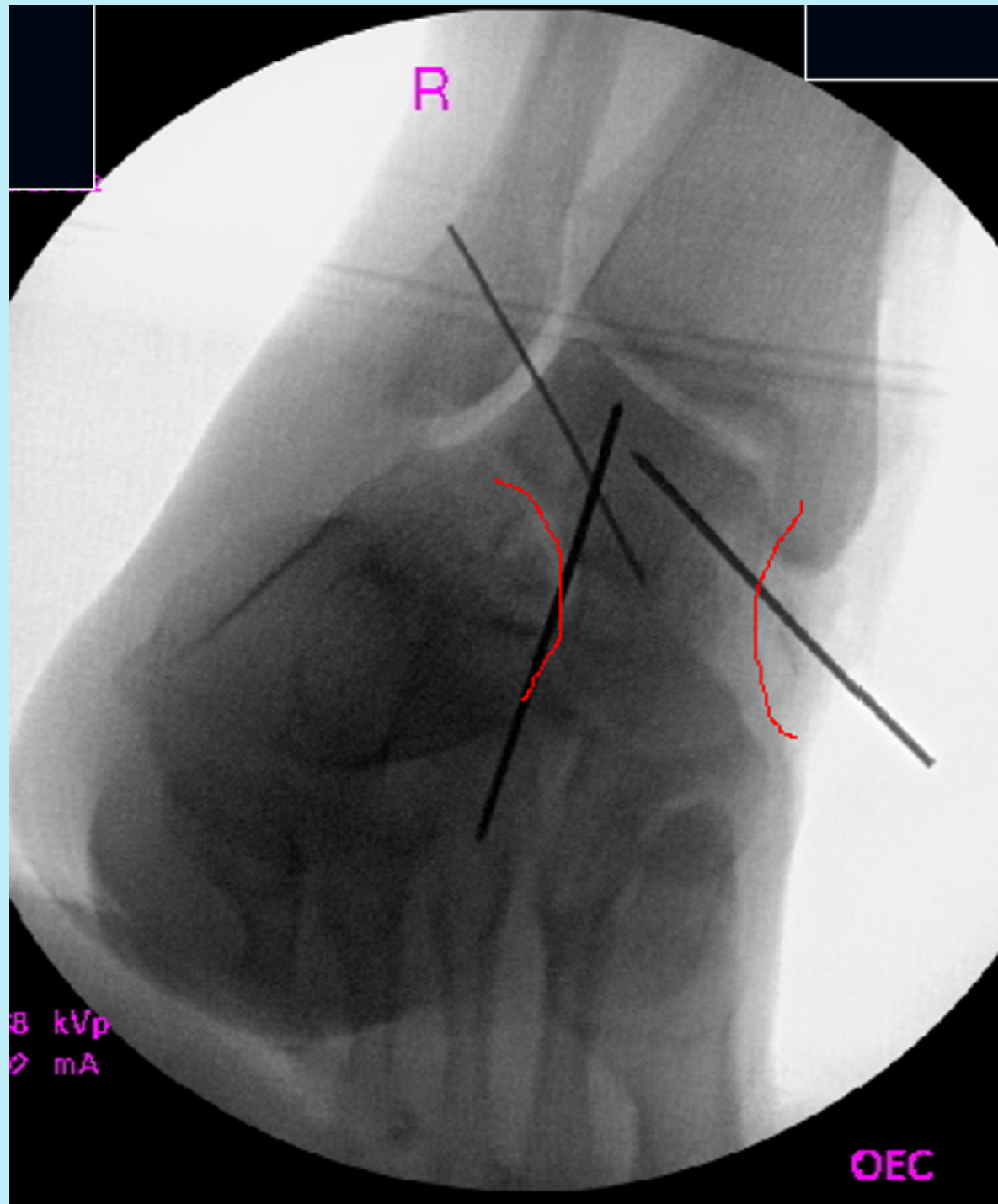
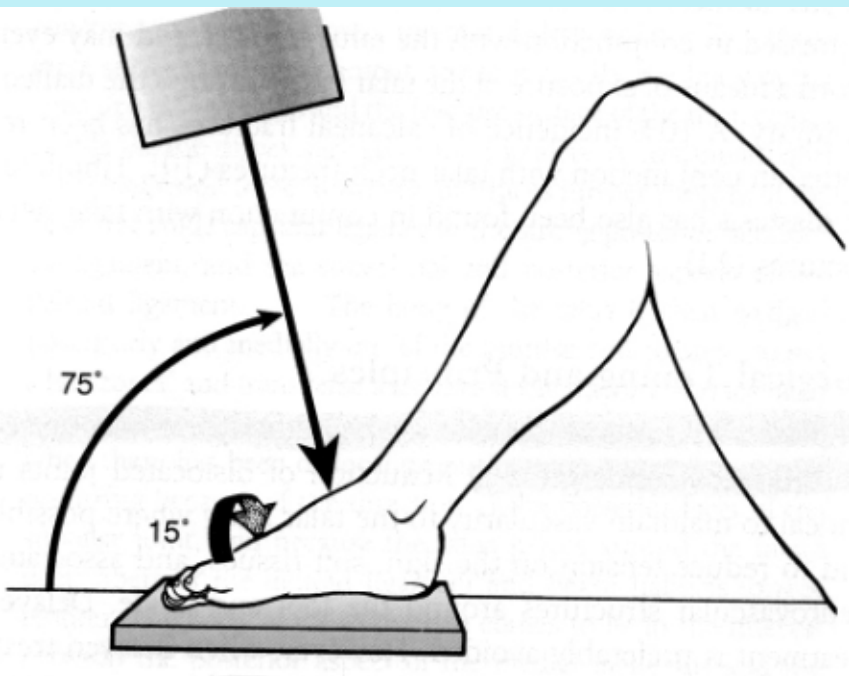


# Canale View

1. Foot is plantigrade on cassette
2. Beam is 75 degrees to perpendicular
3. internally rotate foot 15 degrees



-used to confirm the proper reduction of talar neck fracture intraoperatively  
-goal is to obtain concavity medially and laterally- demonstrates proper alignment of talar neck