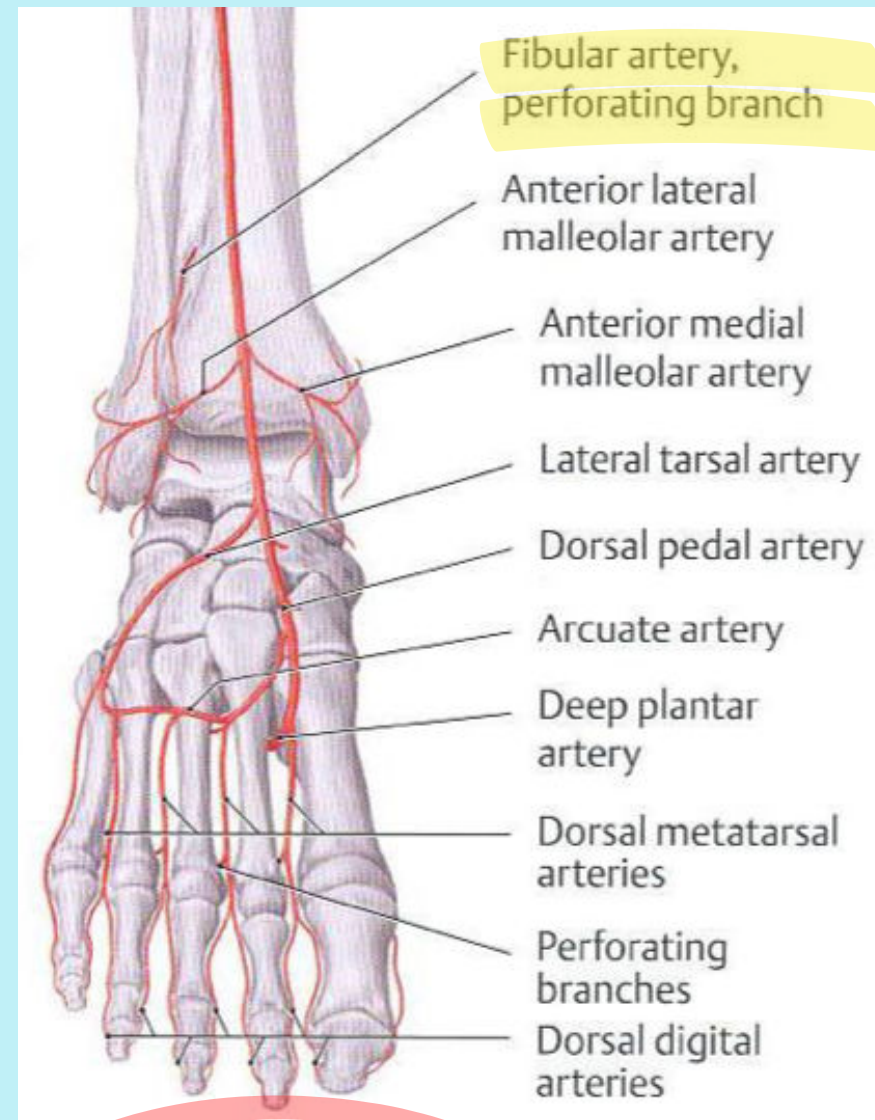


# Lower Extremity Anatomy Review:

## Peroneal Artery

- **Branches of the peroneal artery**

- **Muscular arteries**
  - posterior/lateral compartments of the leg
- **Perforating artery**
  - courses through interosseous membrane proximal to the tibiofibular syndesmosis
  - terminates at the dorsal lateral foot by contributing to the lateral malleolar network
    - sometimes replaces the dorsalis pedis artery



- **Angiosomes of the Peroneal Artery**

- Anterior Perforating Branch
  - anterolateral ankle
- Lateral Calcaneal branch
  - lateral and plantar heel

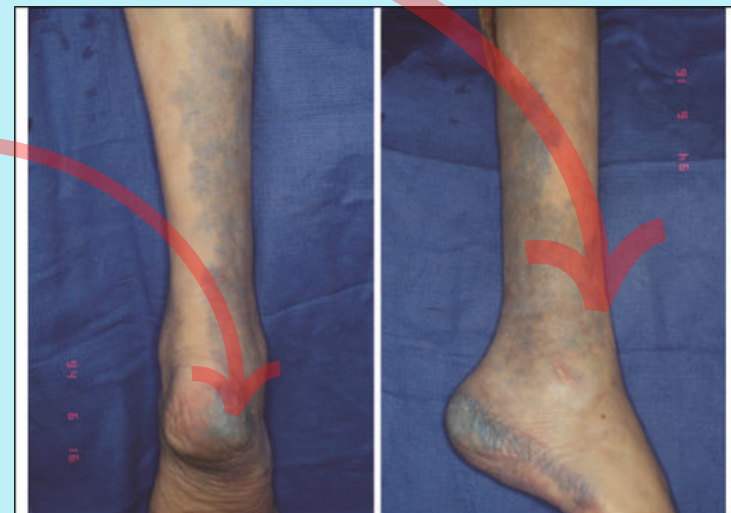

Fig. 15. The peroneal artery's angiosome extends from the midline of the posterior calf (left) to the anterior edge of the lateral compartment (right). It extends inferiorly to the anterolateral ankle and lateral heel. Reprinted with permission from Attinger, C. Vascular anatomy of the foot and ankle. *Oper. Tech. Plast. Reconstr. Surg.* 4: 183, 1997.